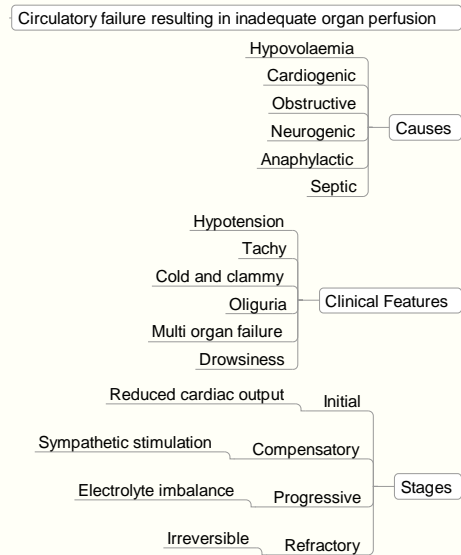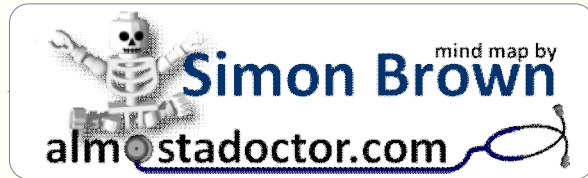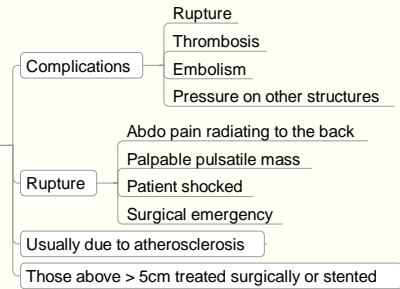


**Shock**

**Aortic Aneurysm**

Permanent localised dilatation of aorta that is expansile



**Disseminated Intravascular Coagulation**

