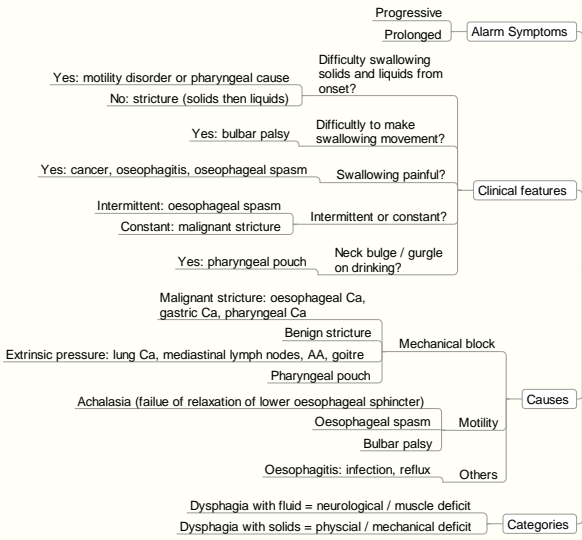


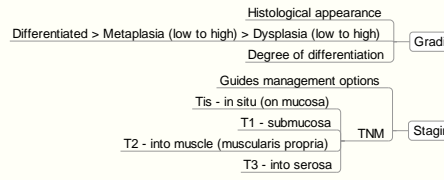


Oesophagus

Swallowing Difficulties

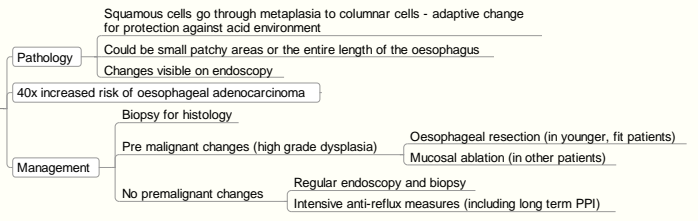


Principles of Grading & Staging

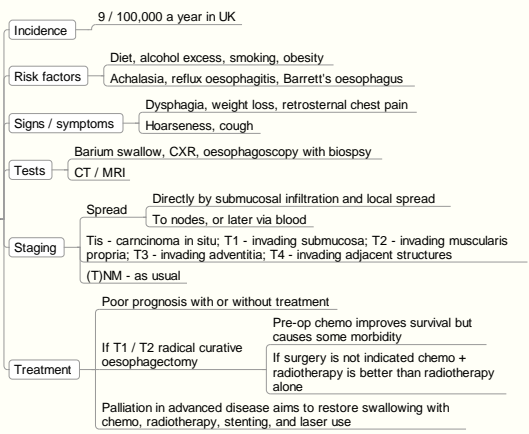


Hiatus hernia - Increased patency of lower oesophageal sphincter

Barrett's Oesophagus



Oesophageal Cancer



Fistula

Abnormal connection between two epithelial surfaces

Stricture

Abnormal narrowing of gut

Oesophagitis

- Range of endoscopic findings from mild redness to severe bleeding
- Excessive mucosal exposure to acid and pepsin can lead to distal oesophageal ulceration in patients with reflux
- Metaplasia can lead to adenocarcinoma
- Bleeding is common but rarely life threatening

Mallory Weiss Tear

Retching / vomiting causing haematemesis via oesophageal tear